



**PATIENT**

Chloe Dalinga

**SPECIES**

Canine

**BREED**

Wheaten Terrier

**SEX**

Female Spayed

**AGE**

9 years

**WEIGHT**

44.1lbs

**INTERPRETED BY**

Maggie Machen Lamy,  
DVM, DACVIM  
(Cardiology)

**IMAGING PERFORMED BY**

S. Barthelemy, DVM

**HOSPITAL NAME**

Signal Hill Animal  
Clinic

**REFERRING VET**

Dr. Cumyn

**INVOICE**

47802

**DATE**

5/8/26

**PRESENTING CLINICAL SIGNS**

History: Recheck echo. Asymptomatic. Possible cardiomegaly on CXR.

-Pertinent previous echo findings (5/2025 MML): CVD B1. Mild MR, mild LAE, trace TR: 2.2m/s. LA: 2.8, LV: 4.4.

**ECHOCARDIOGRAM FINDINGS**

2D, m-mode, color flow and doppler imaging is available. Mild diffuse thickening of mitral valve leaflets with no prolapse into the left atrial lumen. Mild mitral regurgitation with mild left atrial dilation. Normal MR velocity. No LV dilation with borderline myocardial function. The tricuspid valve appears normal with trace tricuspid regurgitation. Normal velocity. Normal right atrial and ventricular diameter and morphology indicating no overt evidence of pulmonary arterial hypertension. The pulmonic and aortic valves are normal in morphology and mobility. Normal pulmonic and aortic outflow velocities with laminar flow. No obvious aortic or pulmonic insufficiency. No pericardial or pleural effusion noted. No obvious cardiac masses.

**CARDIAC CHART**

CANINE CARDIAC PARAMETERS	MR VMAX (m/s)	TR VMAX (m/s)	LA/AO (Boon method)	LA/AO (Heart Base; Swe)	FS (%)	EF (%)	EPSS (cm)
<b>NORMAL PARAMETER</b>	4.5-5.5	<2.7	1.3	<1.6	28-40	40-100	<0.6
<b>PATIENT</b>	5.4	2.0	1.2	1.4	28	60	0.4
CANINE CARDIAC PARAMETERS	HR (BPM)	AV VMAX (m/s)	PV MAX (m/s)	BODY WEIGHT (kg)	LA 2D short axis Base view (cm)	LVIDd Avg; 2D and m-mode short axis (cm)	LVIDs Avg; 2D and m-mode short axis (cm)
<b>NORMAL PARAMETER</b>	50-100	0.7-1.7	0.7-1.6	BELOW	BELOW	BELOW	BELOW
<b>PATIENT</b>	150	1.5	1.0	20.0	2.5	4.1	2.9
*Normal chamber parameters expressed as a mean value (SD)				3	1.27 (5.3)	2.46 (2.46)	1.36 (5.5)
<b>BODY WEIGHT DEPENDENT PARAMETERS</b>				5	1.40 (4.5)	2.74 (5.2)	1.60 (4.7)
<i>*Note: All measurements based upon multi-modal images and methods. An average value is reported.</i>				10	1.50 (3.8)	3.27 (3.5)	2.06 (3.1)
				15	1.83 (2.0)	3.71 (2.4)	2.43 (2.1)
				20	2.02 (1.9)	4.14 (2.2)	2.80 (2.0)
				25	2.18 (2.4)	4.48 (2.9)	3.10 (2.5)
				30	2.33 (3.3)	4.83 (3.9)	3.39 (3.4)
				35	2.48 (4.3)	5.17 (5.0)	3.69 (4.5)
				40	2.62 (5.2)	5.48 (6.1)	3.96 (5.4)
				50	2.88 (7.1)	6.07 (8.3)	4.46 (7.4)

**INTERPRETATION OF THE FINDINGS & FURTHER RECOMMENDATIONS**

Chronic degenerative valve disease persists with evidence of stability. Mild mitral and trace tricuspid regurgitation are unchanged, with stable chamber dimensions. A persistent lack of atrial or ventricular enlargement indicates the current risk for complication remains low. The LV function is borderline for this signalment and continued monitoring is advised. Diet history and thyroid status should be obtained. No concurrent issues such as pulmonary hypertension are identified.



## PATIENT

Chloe Dalinga

## SPECIES

Canine

## BREED

Wheaten Terrier

## SEX

Female Spayed

## AGE

9 years

## WEIGHT

44.1lbs

## INTERPRETED BY

Maggie Machen Lamy,  
DVM, DACVIM  
(Cardiology)

## IMAGING PERFORMED BY

S. Barthelemy, DVM

## HOSPITAL NAME

Signal Hill Animal  
Clinic

## REFERRING VET

Dr. Cumyn

## INVOICE

47802

## DATE

5/8/26

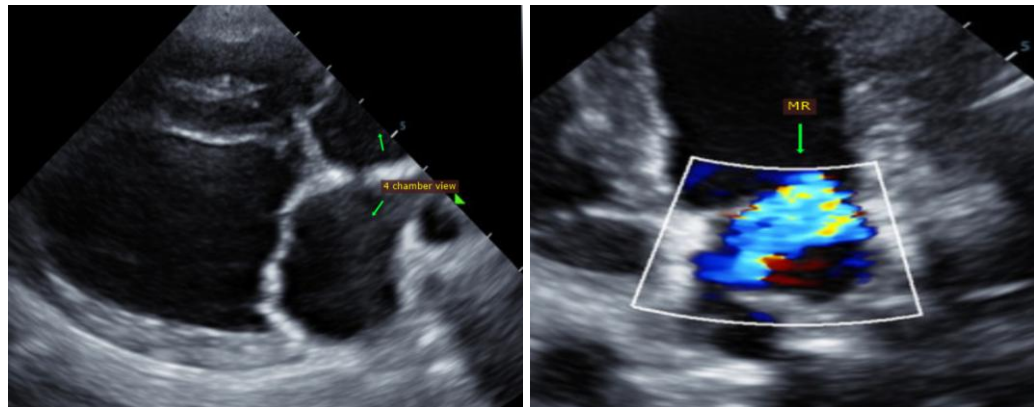
Given these findings, no cardiac medications are clearly indicated. While a lack of significant progression is certainly a good sign, continued monitoring is advised lifelong to determine if and when medications are necessary.

Omega fatty acid supplementation and mild salt restriction may be of some long-term benefit. Monitor for development of a cough, labored breathing, exercise intolerance or collapse episodes.

Anesthetic risk is considered mild if needed. Cardiac protective drug choices (opioid/benzodiazepine premedication, propofol or alfaxalone induction, isoflurane gas) are recommended. Pre-oxygenate for 5-10 minutes prior to induction. Monitor for arrhythmias, hypotension, and hypoxia both intra and post-operatively and intervene as necessary. Mild IV fluid restriction is recommended to avoid fluid overload. Avoid heart rate stimulating drugs such as atropine unless clinically indicated.

Recommend conservative monitoring with a recheck echocardiogram in 6-12 months, sooner if any development of clinical signs in the interim.

## IMAGES



**The information and recommendations provided are based on the images presented by the referring veterinarian. No evaluation can be communicated regarding pathology that was not visible in the image/video clips provided.**

Thank you for this referral. This report was generated using transcription software, and minor dictation errors may be present. If the clinical or image interpretation does not parallel your findings or if I can be of any further assistance, please contact me.

**Maggie Machen Lamy, DVM**  
**Diplomate of the American College of Veterinary Internal Medicine (Cardiology)**  
info@sonopath.com